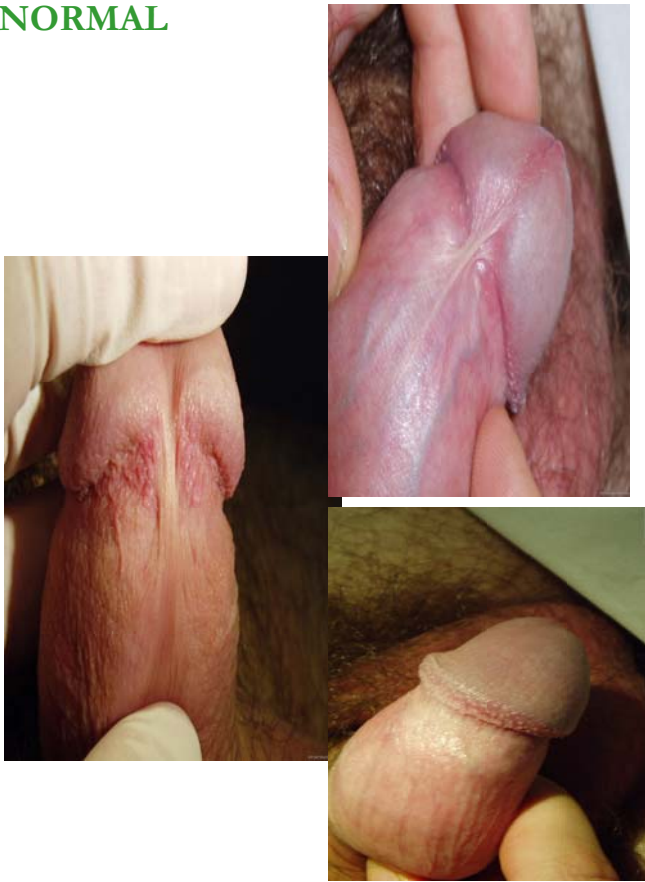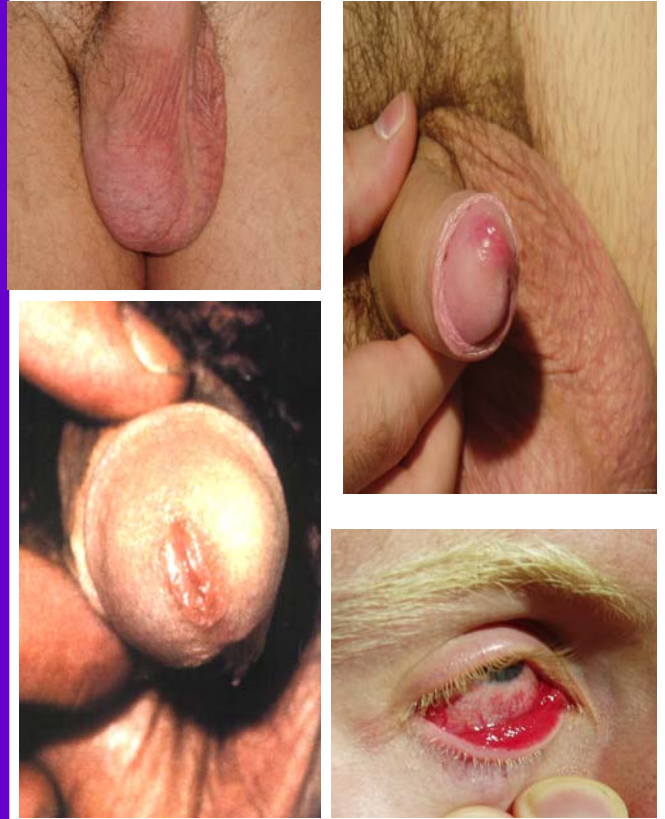


Pictures courtesy of Dr Stuart Aitken
VISIT OUR WEBSITE FOR OTHER PICTURES

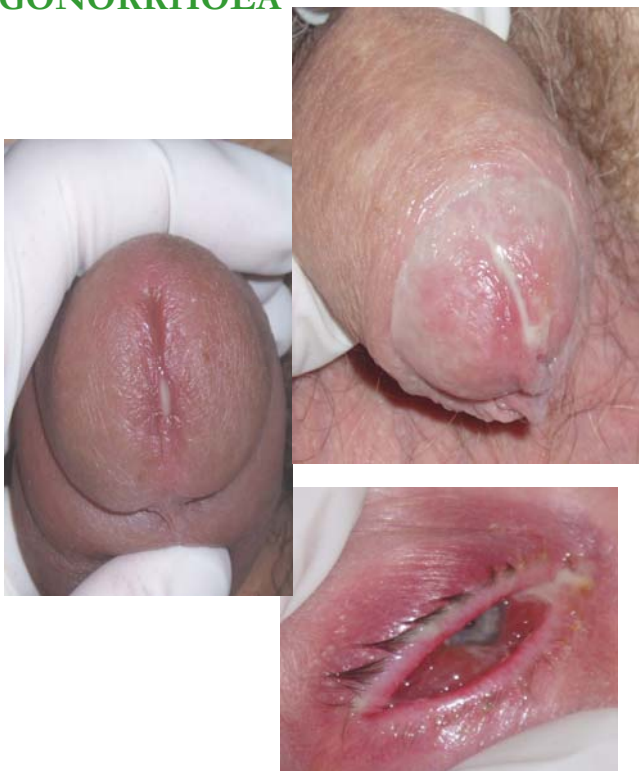NORMAL



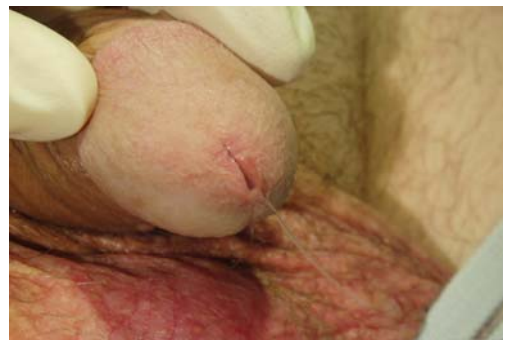CHLAMYDIA



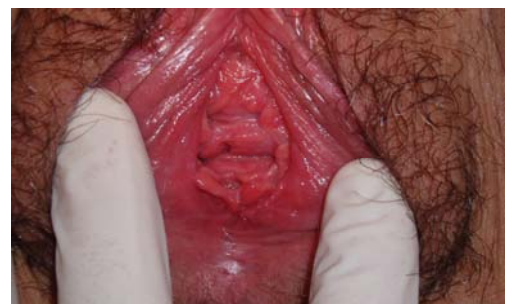GONORRHOEA



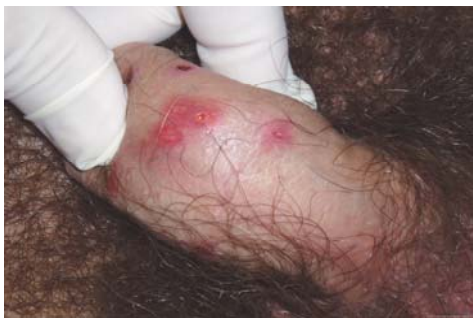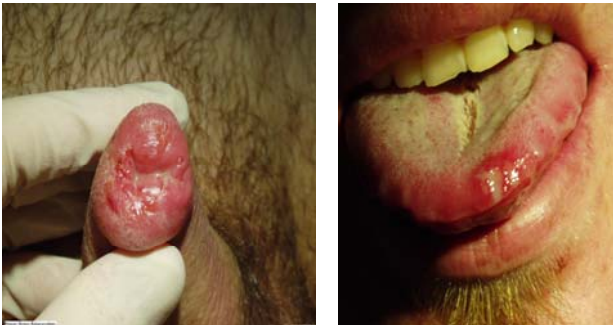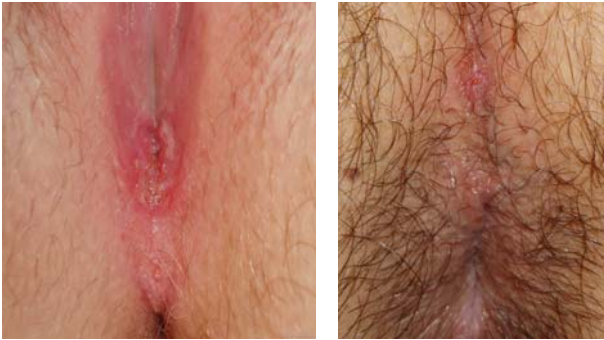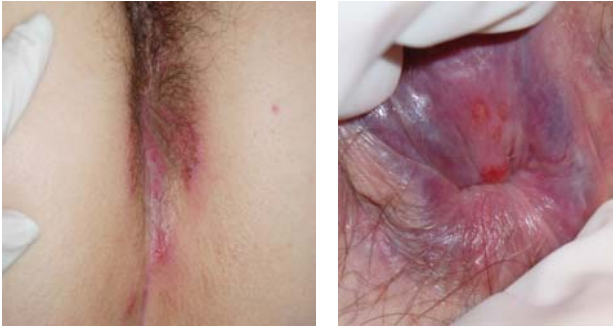NSU



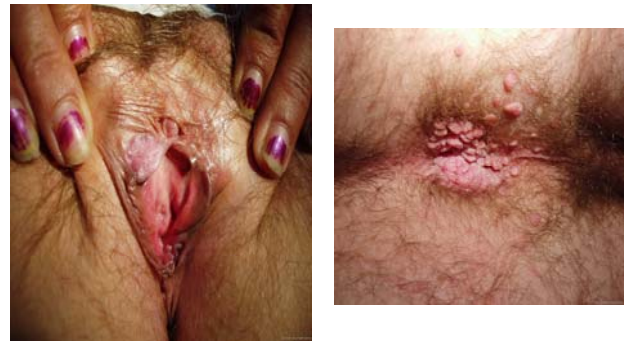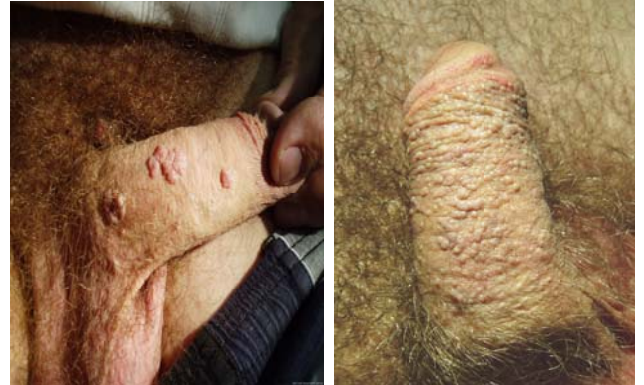CANDIDA



HERPES

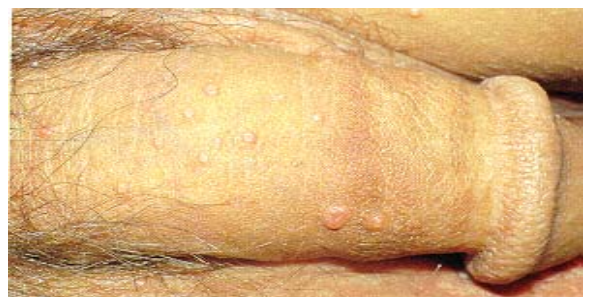
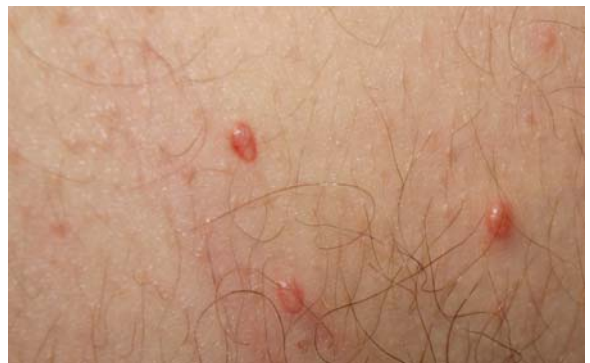
WARTS



Precancerous lesion
caused by warts

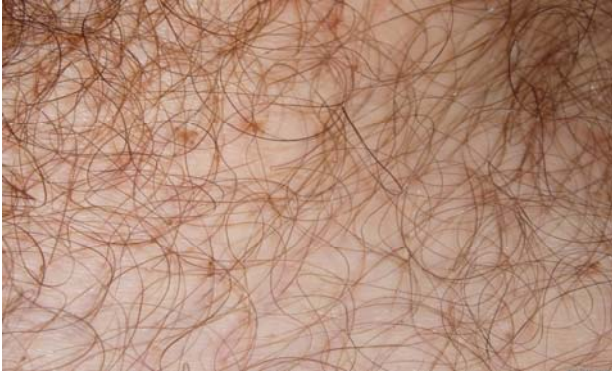MOLLUSCUM



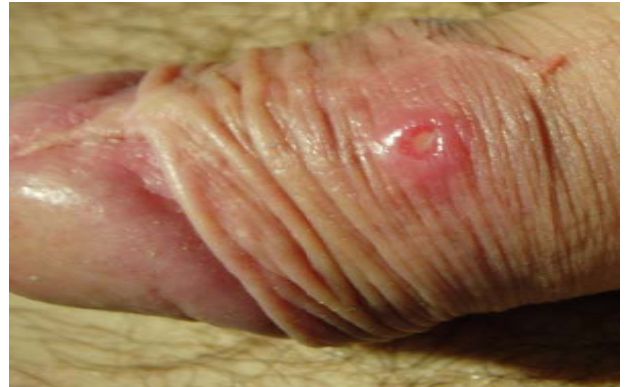Pictures courtesy of Dr Stuart Aitken

VISIT OUR WEBSITE FOR OTHER PICTURES

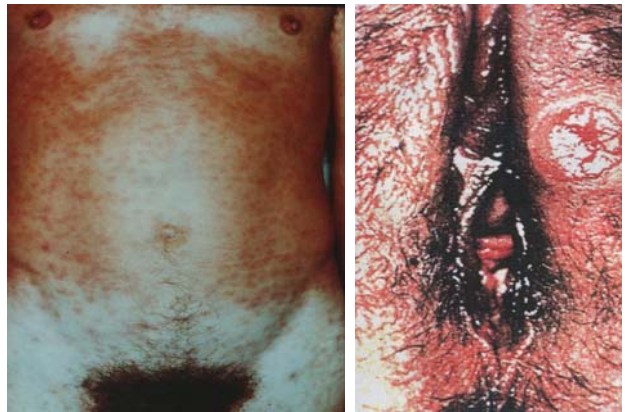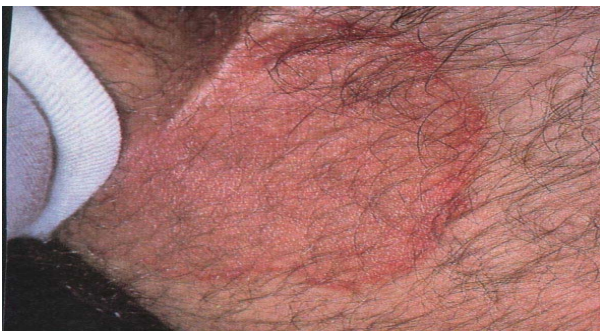CRABS



SYPHILIS

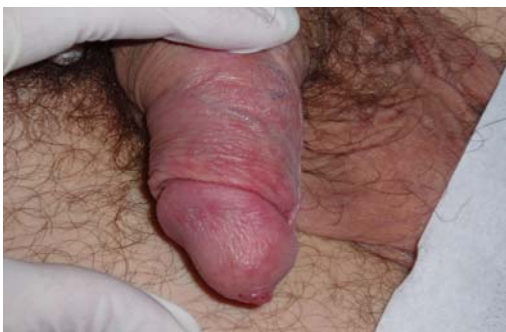
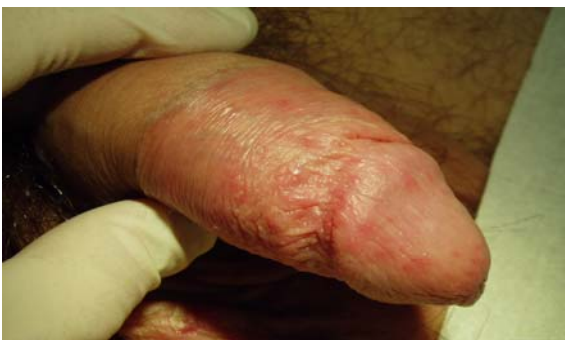
JOCK ITCH / TINEA



BALANITIS (NOT STI)

(It is an infection under the foreskin)



SCABIES

